

## INTRODUCTION

The association of facial rejuvenation techniques to aesthetic dentistry can have a major impact on the aesthetic outcome. One common clinical condition, that is not always resolved by increasing the reestablishment of occlusal vertical dimension, is the downwards of the corner mouth.<sup>1,2</sup>

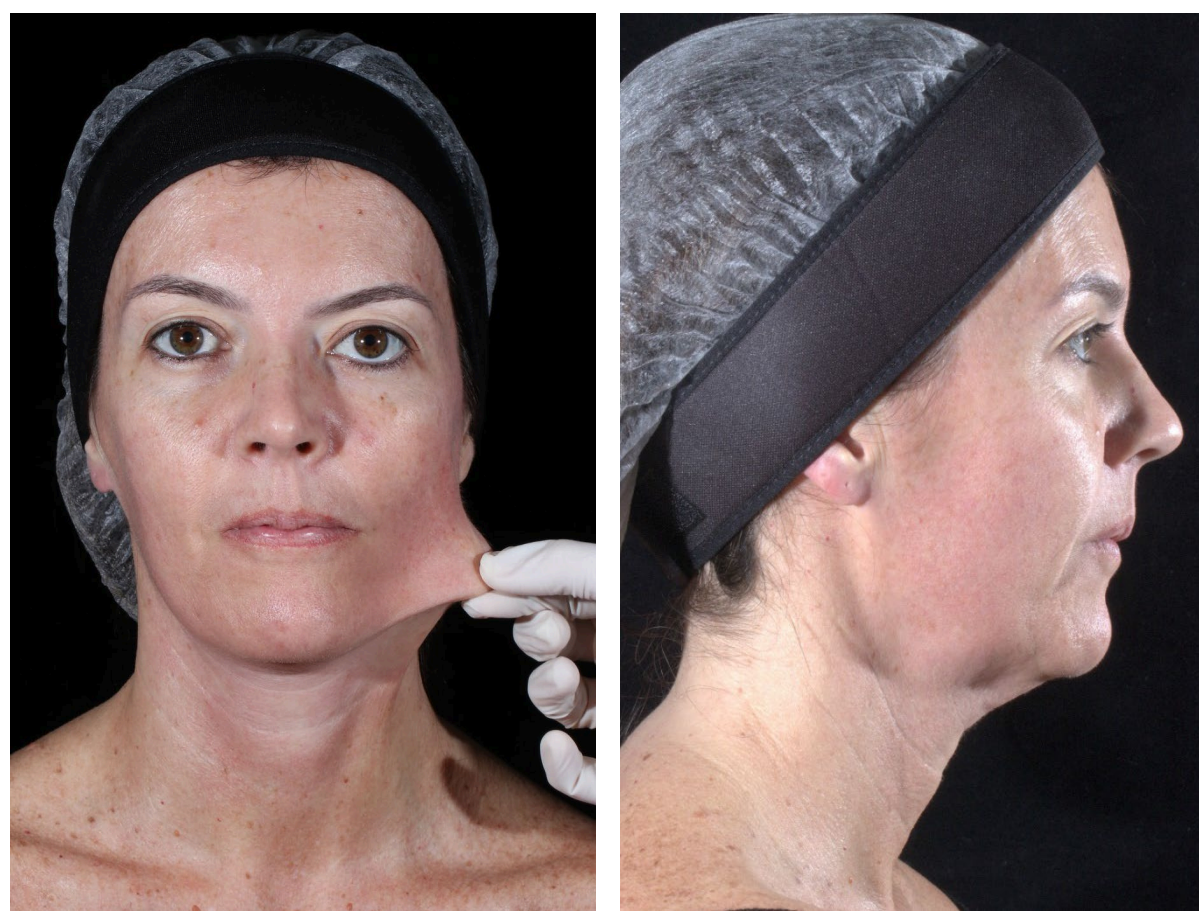During aging, the oral commissures depress over time partly due to increased contractility of the depressor anguli oris (DAO) muscles, sagging of facial fat pads (jowling), and deterioration of skin smoothness.<sup>3</sup>

When the corners of your mouth droop downwards, it looks like you are permanently giving a sad or stern expression. Furthermore, drooping mouth corners create a natural pathway for saliva to escape down the marionette lines. This can be caused not only by a reduced occlusal vertical dimension, but also by genetics and gravity, besides the interaction of the perioral muscles affects the position of the oral commissures.

Recently, nonsurgical techniques have been described to lift or rejuvenate oral commissures (injecting botulinum toxin, fillers or a combination of these).<sup>3</sup>

This clinical case described the association of Botulinum toxin injection as well as calcium hydroxylapatite (CaHA) in the lift of corner mouth. The procedure leads to rejuvenation and also inhibits the impairment of saliva in the corner mouth, an important factor to prevent fungal proliferation and prevent any disease.

## METHODS & MATERIAL



A 47-year-old female patient presented for a cosmetic consultation regarding her unbalanced facial profile (Fig.1). Clinical examination revealed she had sagging face skin, soft tissue ptosis, misaligned jaw, change in the position of the fat pads and in the position of the angle of the mouth.

Fig. 1

Documented data included age, sex, health issues, treatment indication, injection sites, injection technique, injection depth and the injected volume. The validated photo-numeric 5-point Merz Aesthetics Scale for jawline was used to objectively rate age-related skin changes and evaluate the improvement in baseline scores for midface, lower face and jawline contour (Fig.2)

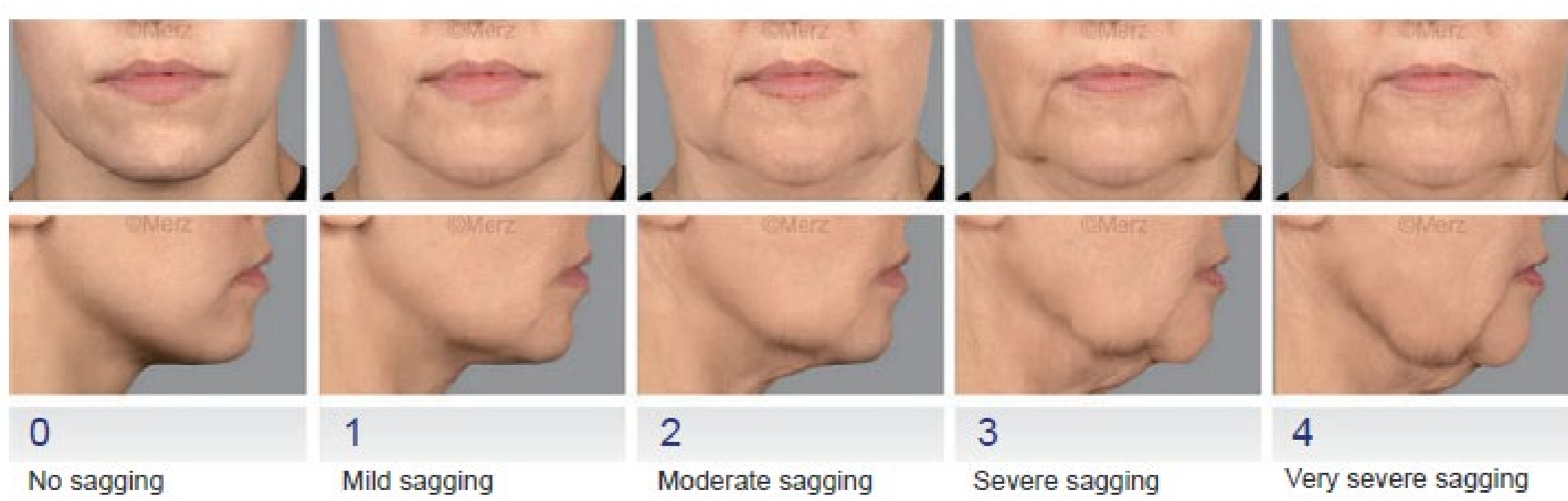

Fig. 2 Merz Aesthetics Scale: a validated, objective, quantitative rating scale for evaluating the esthetic signs of aging

The patient was subjected to:

- Bilateral therapy injection of 3UI BTX-A (Xeomin®, Merz Aesthetics) at depressor anguli oris (DAO) (Fig.3)
- 1,5 ml Calcium hydroxylapatite with 0.3% integral lidocaine (Radiesse® Lidocaine (+), Merz North America, Inc, Raleigh, NC) by injecting in the left and right malar area, anterior cheek, left prejowl sulcus and jawline, using a serial puncture technique with a 27G needle in the supraperiosteal area (Fig. 4).
- Injections of 1,5 ml of calcium hydroxyapatite (CaHA, Radiesse, Merz Aesthetics) injected subcutaneously with threading technique with cannula (22 gauge, 1.6") in a few bands of the product delivered in parallel rows in the left and right malar area, anterior cheek, left prejowl sulcus and temples (fig.5).

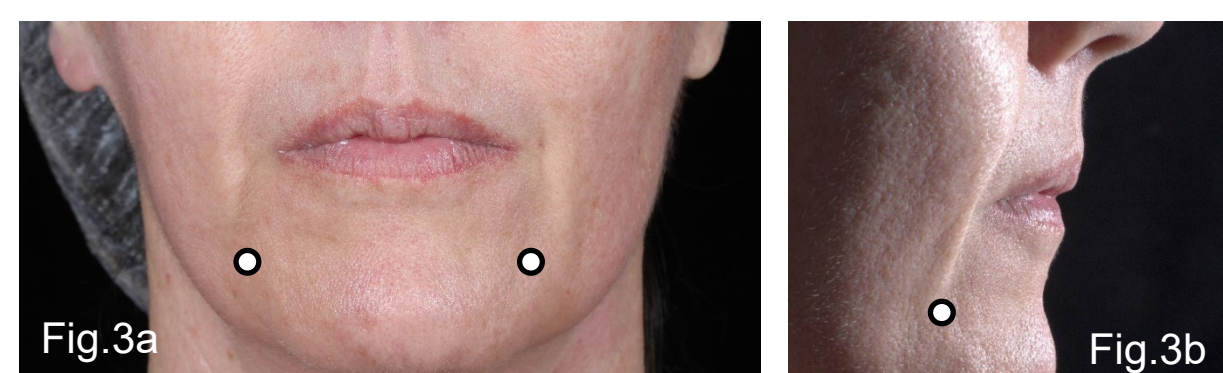

Fig.3 depressor anguli oris: Bot (Fig n°), ulinum toxin injection area. a) frontal view; b) side view

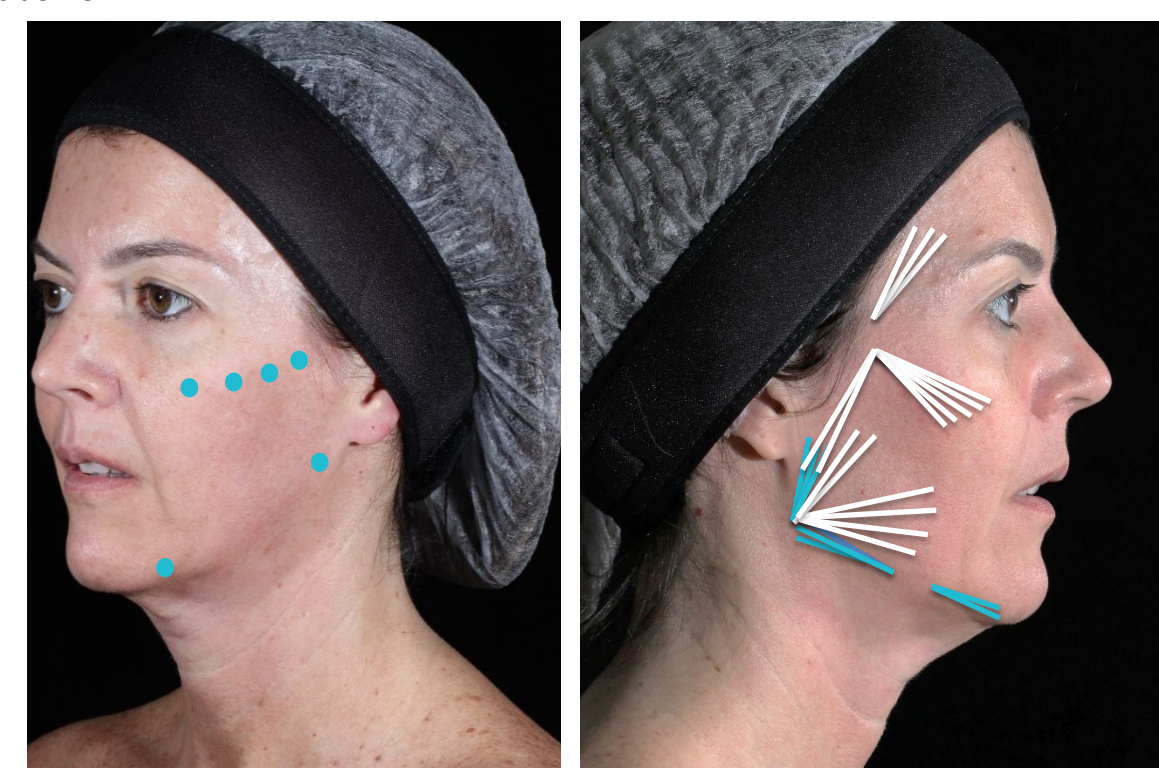


Fig.4 Techniques for CaHA (+) biostimulation of the face: combining Radiesse® (White line) and : Radiesse Lidocaine® (Blue line) injected subcutaneously.



Fig.5. injection area

## RESULTS

CaHA fillers are effective and safe to be used for facial rejuvenation. In this case report, the procedure produced significant improvements in facial contour with natural results. Achieving beauty is not about creating transformation in the patient, but about creating a natural harmony of the smile in the context of the face. Results of treatment are shown in Figure 6 that clearly illustrate lifting of the entire composite flap and expansion of overlaying tissues, resulting in a better position of the corners of the mouth .

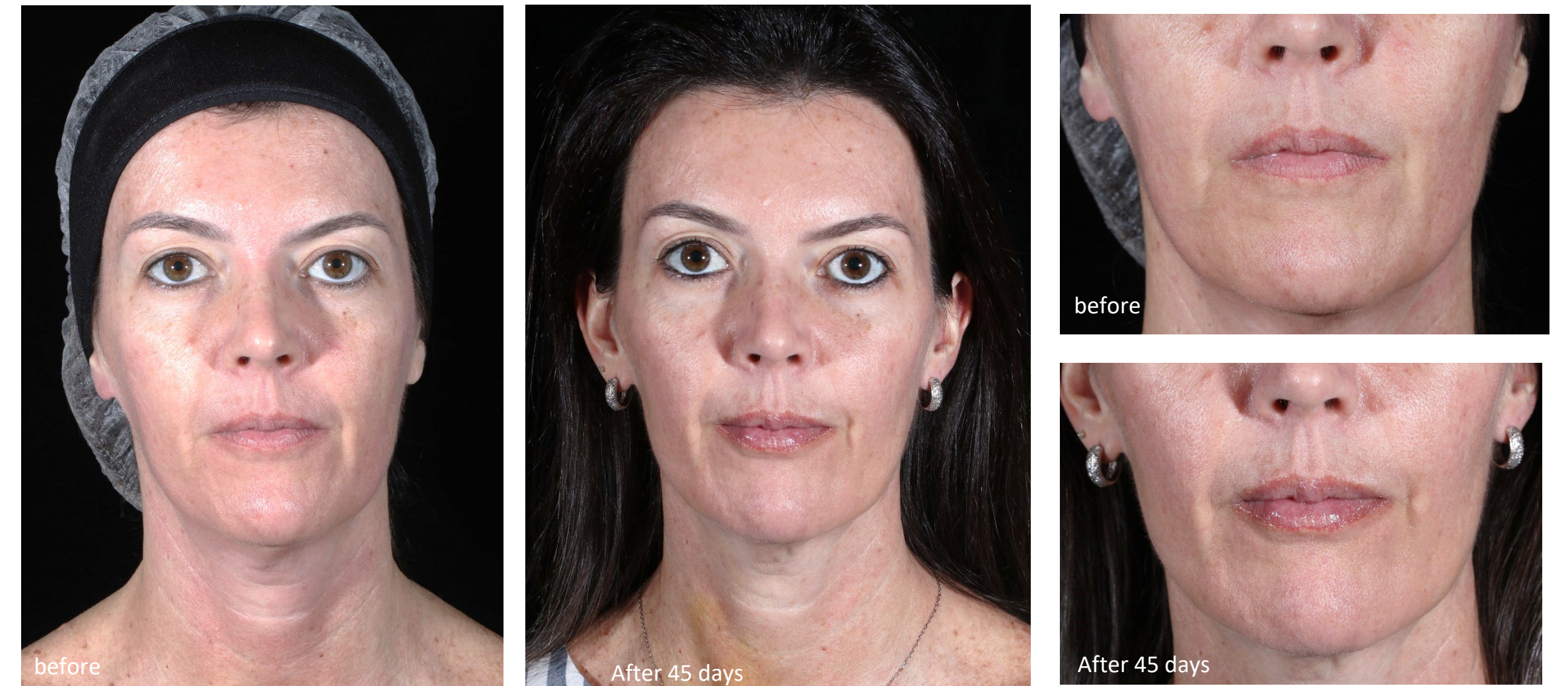


Fig.6 The face before and 6 weeks after injections of Botulinum Toxin A and injections of 1.5mL of CaHA (Radiesse) diluted 1:1 with 1.5mL of lidocaine and 3mL of CaHa + (Radiesse® Lidocaine). Notice the improvement of skin laxity and the discrete volume gain, besides the corner mouth lift. Results of just one session.

Results showed that aesthetics and function was increased by the combined treatment with the use of botulinum toxin (Xeomin®) and injection of CaHA (Radiesse® & Radiesse Lidocaine®) was effective and well tolerated for the rejuvenation of aging, face countour and for corner mouth lift. (Fig.7)

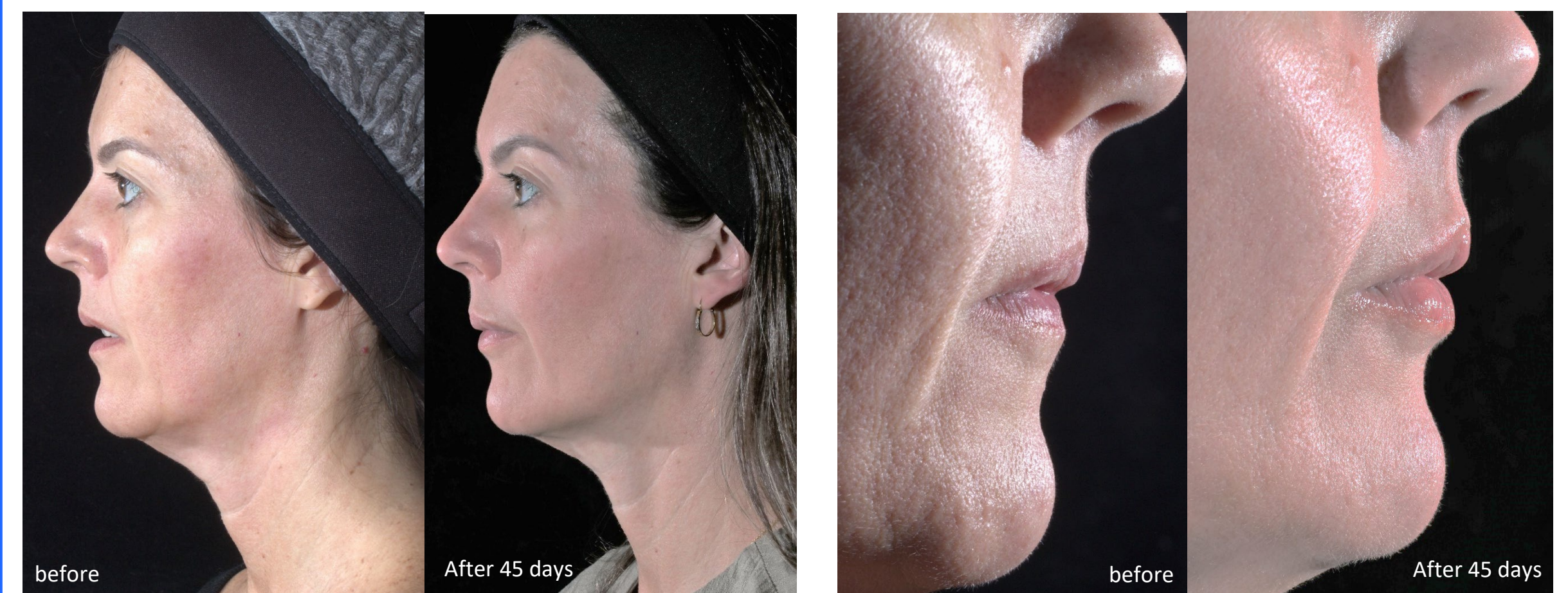

Fig.7 Pictures before and after the treatment

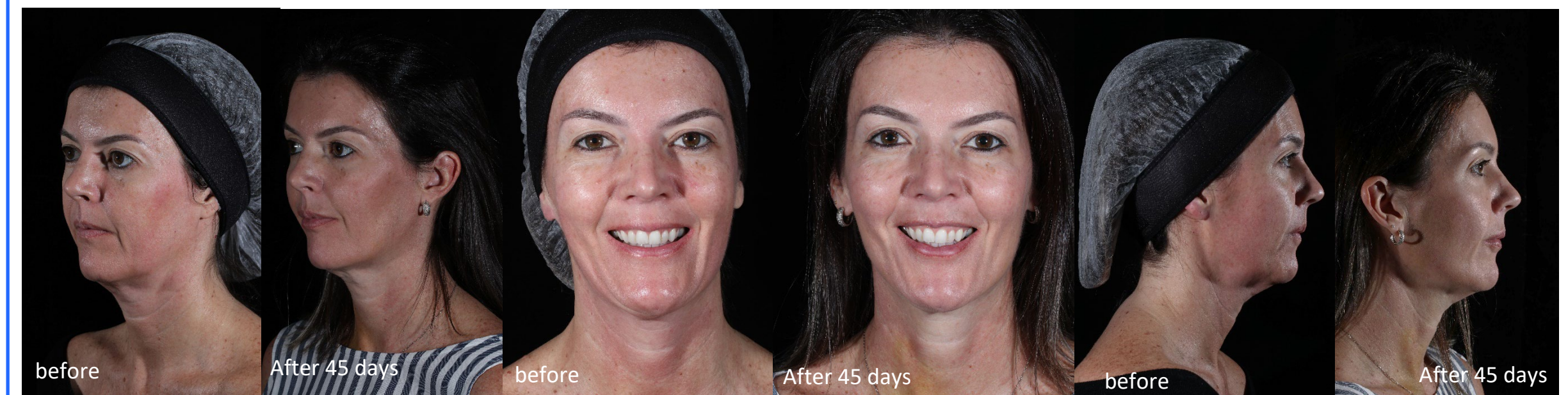

Fig.7 The face before and 6 weeks after injections of Botulinum Toxin A and CaHA (Radiesse) combined to injections of CaHa + (Radiesse® Lidocaine). Results of just one session.

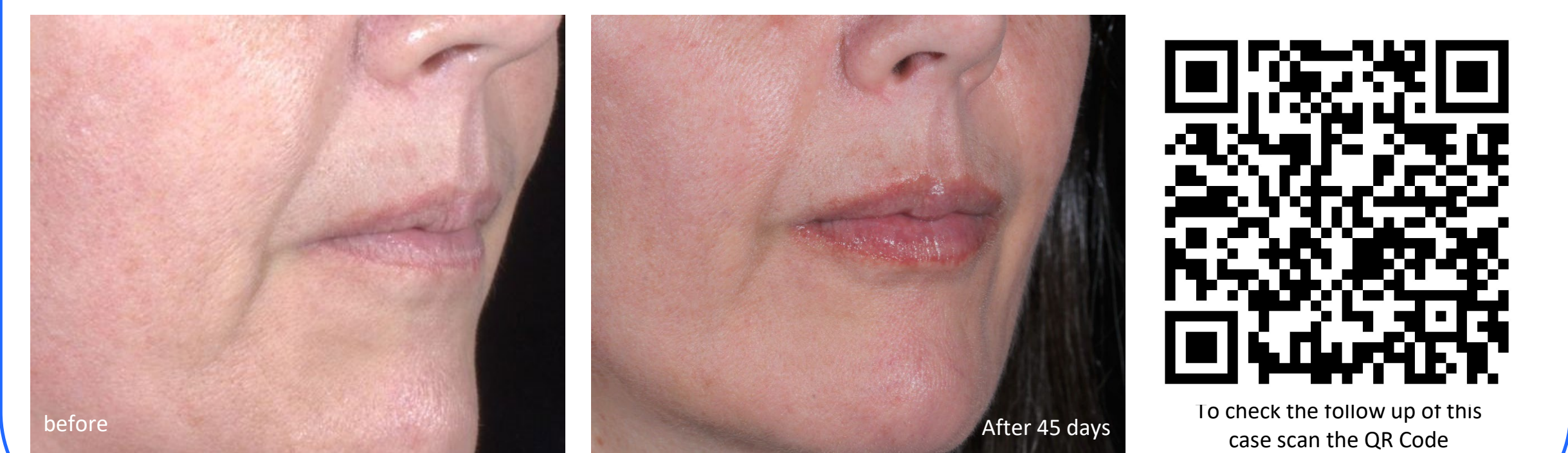

Fig.7 Pictures before and after the treatment

To check the follow up of this case scan the QR Code

## CONCLUSION

The results of this study support the neuromodulation and lifting effectivity of the combining techniques between Botulinum Toxin and Calcium Hydroxylapatite for corner mouth lift.

CaHA has demonstrated safety and effectiveness in the treatment of marionette lines impacting the position the corners of the mouth.

The success of an esthetic treatment relies on good planning

1. Romeo, G. Smile makeover and the oral facial harmony concept in a new era: relationship between tooth shape and face configuration. Int J Esthet Dent. 2021 May 10;16(2):202-215.  
2. N. K. Mohindra and J. S. Bulman. The effect of increasing vertical dimension of occlusion on facial aesthetics. BRITISH DENTAL JOURNAL VOLUME 192 NO. 3 FEBRUARY 9 2002  
3. Nanouk van der Sluis, MD, Haydar A Gülbitti, MD, Joris A van Dongen, MD, PhD, Berend van der Lei, MD, PhD, Lifting the Mouth Corner: A Systematic Review of Techniques, Clinical Outcomes, and Patient Satisfaction, *Aesthetic Surgery Journal*, Volume 42, Issue 8, August 2022, Pages 833–841.